

Table of Contents

Burt, Spencer - #5717 - Natural History of Untreated Stage 3 Retinopathy of Prematurity by Ultra-widefield Optical Coherence Tomography	1
Abstract submission for Institutional Repository	1



Research Week 2024

Natural History of Untreated Stage 3 Retinopathy of Prematurity by Ultra-widefield Optical Coherence Tomography

Spencer S. Burt, Mani Woodward, Shuibin Ni, Susan Ostmo, Aaron Coyner, Yali Jia, David Huang, Yifan Jian, J. Peter Campbell, Benjamin K. Young

Casey Eye Institute, Oregon Health and Science University

Keywords

Retinopathy of prematurity, progression, regression, stage 3

Abstract

Purpose

This retrospective case series aims to classify the natural progression and regression of the ridge in stage 3 retinopathy of prematurity (ROP) using ultra-widefield optical coherence tomography (UWF-OCT) images.

Methods

A prototype UWF-OCT device was used to capture *en face* scans ($>140^\circ$) from infants monitored for ROP in the Oregon Health and Science University neonatal intensive care unit whose parents consented to study participation between December 2020 and February 2024. Infants who developed stage 3 ROP and were never treated were reviewed retrospectively for trends in ridge progression and regression.

Results

In all six patients who met inclusion criteria, the temporal ridge persisted the longest as the ridge dissipated elsewhere over time (Figure 1). All those observed remained without plus disease, and none proceeded to stage 4 disease. Patient demographics can be seen in Table 1.

Conclusion

The temporal ridge in untreated patients with stage 3 ROP appears to regress more slowly compared to the ridge in other regions of the retina. This may be caused by increased release of vascular endothelial growth factor temporally because of the larger area temporally of avascular retina in infants with ROP.

Figures and Legends

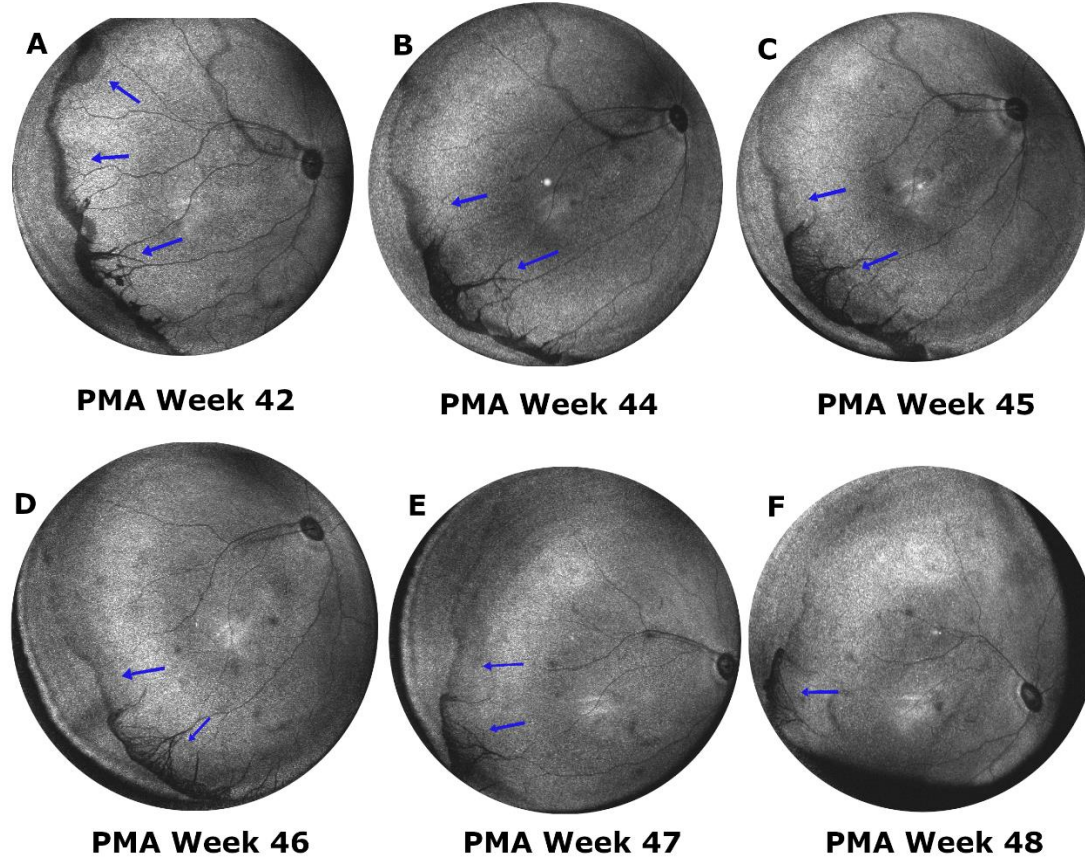


Figure 1. Sample ultra widefield optical coherence tomography images of an infant born at 25 weeks and 795 grams. Arrows indicate the ridge. The images demonstrate the comparatively slow temporal ridge regression.

Patient	Sex	Parent reported race	Birthweight (grams)	Gestational age (weeks)	Initial zone	Normal/Pre-Plus/Plus
1	Male	Caucasian	755	25	2	Pre-plus
2	Female	Caucasian	575	24	1	Pre-plus
3	Male	Caucasian	680	23	1	Pre-plus
4	Female	Caucasian	584	25	2	Pre-plus
5	Female	Caucasian	675	24	2	Pre-plus
6	Male	Caucasian	795	25	2	Pre-plus
Average	NA	NA	677.3	24.3	1.7	NA

Table 1. Demographics of infants with retinopathy of prematurity who developed stage 3 but did not require treatment.