



THE ARTERIAL BLOOD SUPPLY OF THE PANCREAS

by


JOHN M. PIERSON

A THESIS

**Presented to the Department of Anatomy
and the Graduate Division of the University of Oregon Medical School
in partial fulfillment
of the requirements for the degree of
Master of Science**

December 1943 2

APPROVED:



(Professor in Charge of Thesis)



(for the committee)

May 17, 1943

THE ARTERIAL BLOOD SUPPLY OF THE PANCREAS

An artery supplying the pancreas was first pictured and briefly described by Vesalius¹ in 1564. The supply was more completely described by Winslow², Haller³, and Bell⁴. Modern anatomy texts have followed the works of Vernouil⁵ and other anatomists of the early 19th century, leaving unused the more accurate descriptions of the earlier and subsequent investigators. Since then, Sappey⁶, Wiart⁷, Rio Branco⁸, Brun⁹, Testut¹⁰, Lipshutz¹¹, Romodanowskaja¹², Adachi¹³, Petren¹⁴, Wharton¹⁵, and Ziegler¹⁶ have contributed substantially to our understanding of the vessels supplying the pancreas. Many others have written articles of interest on this subject, but each of the above-named men has contributed at least one new and important finding which bears on this subject. The reader is especially referred to Petren's monograph on the arterial and venous supply of the duodenum and head of the pancreas¹⁴. The works of Romodanowskaja¹² and Ziegler¹⁶ are also of particular importance.

For the surgeon, any description of the blood supply to the pancreas without some mention of the vessels supplying the duodenum is incomplete, since the relationship of the two organs is most intimate. A concise, accurate description of the arterial supply to the first part of the duodenum is given by Wilkie¹⁷.

Dissections were made of arterially embalmed and injected cadavers in the anatomy laboratories of the University of Oregon Medical School and of specimens from autopsies which were injected

with a gelatin color mass and fixed in 60 per cent formalin solution. In all, 50 dissections were performed. Percentages quoted below are in some instances computed from slightly less than the total number because of difficulties of dissection encountered in parts of the region dissected. Unless specified, percentages given are of the writer's series of cases. The vascular pattern here described has been limited to the most constant vessels and those of greatest surgical significance.

Typically (Fig. 1.) the pancreas is supplied by two arteries from the gastroduodenal, two from the superior mesenteric, and one from either the splenic, hepatic, or celiac arteries. In addition to these a variable number of small arteries arise from the splenic, gastroduodenal, and hepatic. The larger vessels arising from the gastroduodenal artery are the superior pancreaticoduodenal arteries (right pancreaticoduodenal of some authors). These are two in number, an anterior and a posterior. They anastomose with corresponding anterior and posterior inferior pancreaticoduodenal arteries (left pancreaticoduodenal) from the superior mesenteric (Fig. 1.). These vessels form two arterial arcades, one on the posterior surface of the head of the pancreas, the other, except for its lowermost part, on the anterior surface. They are respectively the posterior and the anterior arcades of the pancreas. The two inferior pancreaticoduodenal arteries usually arise in a common trunk from the superior mesenteric, the common inferior pancreaticoduodenal artery. The superior

pancreatic artery is the least constant of any of the large arteries to the pancreas. When present, it arises from the splenic, hepatic, or directly from the coeliac arteries. In addition to the arteries mentioned above an inferior pancreatic artery, which passes along the inferior margin of the body to the tail, may take origin from the superior mesenteric, the inferior pancreaticoduodenal, or the superior pancreatic artery.

The pancreaticoduodenal arteries are usually at least 2 mm. in diameter, the superior nearly always being larger than the inferior. The superior pancreatic artery is most commonly 1.5 mm. and the inferior pancreatic 1.0 to 1.5 mm. in diameter. All other vessels mentioned are usually 1.0 to 1.5 mm. in diameter.

The gastroduodenal artery (Figs. 1,2,5,6.) arises from the hepatic just dorsal and slightly superior to the junction of the pylorus and the duodenum. Whereas the hepatic passes upward in the hepatoduodenal ligament, medial to the common duct and anterior to the portal vein, the gastroduodenal courses downward, medial to the common duct and dorsal to the first part of the duodenum to terminate at its lower border by dividing into the right gastroepiploic and anterior superior pancreaticoduodenal arteries. As the gastroduodenal passes dorsal to the superior margin of the duodenum, it gives off the posterior superior pancreaticoduodenal artery. Two smaller branches are given off to the first part of the duodenum (Figs. 1,5.): the supraduodenal artery to the superior wall and most of the anterior surface, and the retroduodenal artery (Fig. 1.) arising one-half inch above the bifurcation of the

gastrooduodenal and supplying the lower two-thirds of the posterior wall, sometimes extending as far as the second part. The remainder of the first part of the duodenum is supplied by branches from the pyloric, the right gastrosplenic, and the superior pancreaticoduodenal arteries. A few variable and unnamed branches may be given to the head of the pancreas.

The posterior superior pancreaticoduodenal artery (Figs. 1, 3, 4, 5, 6.) (superior right pancreaticoduodenal) is a surgically important artery, 2 mm. in diameter, which has escaped mention in modern textbooks of anatomy in spite of its occurrence in 96 per cent of the 50 cases dissected. Edwards¹⁶ found this artery in 97 per cent of 100 cadavers but mistook it for the retrooduodenal artery described by Wilkie¹⁷. It takes origin from the right dorsal side of the gastrooduodenal and in 86 per cent of cases (Petron) passes to the right and inferiorly across the anterior surface of the common bile duct. It then curves downward from the right side of the duct toward the left, crossing dorsal to the intrapancreatic part. Thus, the common duct passes through an arterial loop formed by this artery (Figs. 1, 4, 5.). Petron found that in 14 per cent of cases the gastrooduodenal artery lies directly anterior to the common duct where this artery comes off. In these cases the anterior part of the loop is absent (Fig. 3.). It passes downward in an arc to anastomose with the posterior inferior pancreaticoduodenal artery. As it loops over the common bile duct, it nearly always contributes small branches to it (Figs. 1, 5.). Commonly one of these extends up the wall of the

common and cystic ducts (Fig. 5.), sometimes being developed to such a degree as to form an accessory cystic artery. Section and ligation or transplantation of the common duct might lead to necrosis by interfering with these blood vessels. This may explain the leakage of bile common after these procedures.

The posterior arcade is usually situated cephalad to the anterior arcade. The fine branches of the posterior arcade anastomose with each other, forming secondary and tertiary arcades more frequently than do those of the anterior arcade (Fig. 4.). Short branches from it supply pancreatic tissue; longer, more superficial branches supply the duodenum.

The anterior superior pancreaticoduodenal artery (Figs. 1,2,6.) (superior pancreaticoduodenal, right inferior pancreaticoduodenal) arises as a terminal branch of the gastroduodenal in 100 per cent of the cases examined. It comes off just above the lower wall of the first part of the duodenum. In 76 per cent of these cases the arcade passes directly downward and then curves slightly to the left over the anterior surface of the head of the pancreas, many times being partially imbedded in it but nearly always visible from in front (Fig. 2.). This first part of its course lies 1.5 to 2 cm. away from the anterior groove between pancreas and duodenum. As it descends, it approaches the groove more closely until at the junction of the horizontal and the ascending parts of the duodenum it reaches it and bends sharply around the inferior margin of the pancreas, or passes through it. Finally it passes dorsally and upward to the left to lie in its last fifth

on the posterior surface of the head of the pancreas, or within the substance of the gland. That portion of the arcade lying on the anterior surface of the gland is often quite tortuous. In 24 per cent of cases the anterior arcade lies throughout its course on the anterior surface of the head of the pancreas. In these cases, although the arcade approaches the groove between gland and duodenum, it never attains it.

The anterior and posterior inferior pancreaticoduodenal arteries (Figs. 1, 2, 3, 4, 6.) may arise either in a common trunk (62 per cent) or separately (38 per cent) from the superior mesenteric (60 per cent), the first jejunal (26 per cent), or the middle colic artery (14 per cent). They usually (in 64 per cent) arise posteriorly from the superior mesenteric or jejunal arteries. In 36 per cent of cases they arise from the right side, the anterior surface, or the left side of the superior mesenteric artery. Nearly always those arising from a jejunal artery come off dorsally. The origin of these vessels is usually at the lower margin of the neck of the pancreas, but they may come off high behind the pancreas. The duodenojejunal flexure is supplied mainly by branches from one of the inferior pancreaticoduodenal arteries, the first jejunal making a minor contribution to it. Where these vessels may be destroyed it is suggested that the surgeon excise the proximal one or two inches of the jejunum.

The inferior pancreatic artery (Fig. 1.) is constant according to Wharton¹⁵, who found it present in 100 per cent of 30 dissections

and corrosion preparations. It may take origin from the superior mesenteric, the anterior superior pancreaticoduodenal, the inferior pancreaticoduodenal, or the superior pancreatic artery and often receives connections from two or more of these. It passes from the right toward the tail imbedded in the dorsal surface of the body of the pancreas and lies in its entire course within 3 cm. of the inferior margin of the gland. It receives anastomoses from pancreatic branches of the splenic artery.

The superior pancreatic artery (Figs. 1,5,6.) (great superior pancreatic--Haller)* is present in 54 per cent of cases and is quite variable in size. Although usually about 1.5 mm. in diameter, it varies from 1 mm. to nearly 1 cm. This vessel arises from the first 2 cm. of the splenic or hepatic artery or from the celiac axis. It may give origin to the middle colic artery (Fig. 6.) (4 per cent) or may anastomose with it (4 per cent). This artery passes dorsal to the neck or body of the pancreas and the splenic vein. It divides into a branch which passes to the anterior surface of the head to anastomose with a fairly constant branch of the anterior superior pancreaticoduodenal artery (Figs. 1,2,6.). The other branch courses to the left where it usually communicates with the inferior pancreatic artery and may give origin to it. The superior pancreatic artery is not described in any of the

*This is not to be confused with the "great pancreatic" of some textbooks, which is omitted in this discussion since it is rarely found as described.

standard textbooks.

The other pancreatic branches (lesser pancreatic) (Figs. 1, 6.) from the splenic artery are usually quite small, but occasionally one may attain 2 mm. in diameter. They immediately ramify in the substance of the gland, anastomosing with one another and with the inferior and superior pancreatic arteries. They vary in number from two to nine and are always present.

Pancreatic branches of the gastroduodenal (Fig. 1.) are common but variable. They occur in 62 per cent of cases. Most of them tend to occur near the termination of this artery.

Branches of the hepatic supplying the pancreas (Fig. 1.) are inconstant and variable. Vessels 1 mm. or larger in diameter are present in only 10 per cent of cases. They vary in number from one to four, and tend to be present when the hepatic is unusually long or imbedded in the pancreas.

The middle colic artery may have several important relations to the pancreas. It may arise high on the superior mesenteric and be in contact with the pancreas for a short distance. In one case observed it passed through the head of the pancreas, having its major bifurcation while imbedded in the gland. The middle colic may divide near its origin into two or three fair-sized vessels, one of which, enroute to the splenic flexure, may lie imbedded in the pancreas along its inferior margin or in the posterior capsule of the gland. Figure 6 shows one of two cases observed in which the middle colic artery took its origin from the superior pancreatic.

Eigler¹⁶ describes two cases in which the middle colic artery took its origin from the gastroduodenal.

An anomalous hepatic artery arises from the superior mesenteric in 10 per cent of cases (8 per cent right hepatic artery, 2 per cent an accessory hepatic). When present it passes dorsal to the head of the pancreas into the hepatoduodenal ligament, often lying dorsal to the common bile duct. The cystic artery has a similar origin and course in 4 per cent of cases. These anomalous hepatic and cystic arteries always give origin to large branches which supply the posterior surface of the gland and contribute to the posterior arcade.

The relationship of the arteries to the veins is fairly constant. Every artery described above has a concomitant vein. According to the writer's observations, as well as Petren's, the veins usually lie nearer the surface of the gland than the arteries. The anterior superior pancreaticoduodenal vein drains constantly into the right gastroepiploic vein, which is a tributary of the superior mesenteric. The posterior superior pancreaticoduodenal vein almost always drains directly into the portal vein (Fig. 5.). The lower veins empty directly into the superior mesenteric or one of its tributaries. The posterior inferior pancreaticoduodenal vein may empty into the inferior mesenteric. The splenic vein, which is sometimes imbedded in the gland receives several veins from the body and tail.

The author wishes to acknowledge the advice of Dr. Robert S.

Dow and Dr. John A. Gius under whose direction the work was done. He is also indebted to Clarice Ashworth and Clara Pierson for assistance in the preparation of illustrations.

SUMMARY and CONCLUSIONS

A brief review of the literature on the circulation of the pancreas is presented. Observations on the arterial circulation of the pancreas in 50 cases are reported. The arterial supply of the pancreas though variable follows a fairly constant pattern. The anterior and posterior arcades lie on the respective surfaces of the head of the gland. Arteries supplying the pancreas found in this study are:

Anterior superior pancreaticoduodenal in 100%	} form the anterior arcade
Anterior inferior pancreaticoduodenal in 100%	
Posterior superior pancreaticoduodenal in 96%	} form the posterior arcade
Posterior inferior pancreaticoduodenal in 100%	
Inferior pancreatic in 100% (Wharton)	
Superior pancreatic in 54%	
Pancreatic branches of the splenic in 100%	
Pancreatic branches of the gastroduodenal in 63%	
Pancreatic branches of the hepatic in 10%.	

The vessels supplying the first part of the duodenum are: the supraduodenal, the retroduodenal, and branches from the pyloric, the right gastroepiploic, and the superior pancreaticoduodenal arteries.

The arterial loop formed by the posterior superior pancreaticoduodenal artery around the common bile duct is described. Branches from this vessel supply the common duct. It is suggested that

damage to this blood supply may result in leakage of bile following ligation or transplantation of the common duct.

The veins of the pancreas follow the same general course as the arteries but lie superficial to them.

Attention is directed to the posterior superior pancreaticoduodenal, the inferior pancreatic, and the superior pancreatic arteries, which, although of important size and relatively constant occurrence, are uniformly neglected in descriptions of the pancreatic circulation found in standard anatomy textbooks.

Since the duodenojejunal flexure is supplied mainly by branches from one of the inferior pancreaticoduodenal arteries, it is recommended that in procedures which might interrupt these vessels the proximal one or two inches of the jejunum be excised.

REFERENCES CITED

1. Vesalius, A. *Anatomies totius, nere insculpta delineato.* Parisiorum, apud A. Wechelum, sub Pogaso, Helioveco, 1564.
2. Winslow, J. B. *Exposition anat. de la structure du corps hum.* Paris, 1732. (from Petrénil)
3. Haller, A. *Disputationes Anatomicarum Selectarum.* Abrum Vandenhoeck, volum 3, Göttingae, 1748.
4. Bell, John. *The Anatomy of the Human Body.* Vol. 2, G. Mundie & Son, Edinburgh, 1797.
5. Verneuil, A. *Memoire sur quelques points de l'anatomie du pancreas.* Gaz. Med. Paris, 1851. (from Petrénil)
6. Sappey, Ph. C. *Traite D'Anatomie Descriptive.* Tome 2 & 4, Adrien Delahays, Paris, 1869.
7. Wiart, P. *Recherches sur la forme et les rapports du pancreas.* J. l'Anat. et Physiol., Paris, 1899. (from Petrénil)
8. Rio Branco, Do. *Essai sur l'anatomie et de la medecine operatoire du tronc coeliaque et de ses branches, de l'artere hepaticque en particulier.* These Paris, 1912.
9. Brun, H. *Zur Mobilisation und Verlagerung des Magens und Duodenums.* Beitr. f. klin. Chir., Bd. 84, S. 305-338, 1913.
10. Testut, L. et O. Jacob. *Traite D'Anatomie Topographique.* 3rd Ed., Tome 2, Octave Doin et Fils, Paris, 1914.
11. Lipskutz, D. *A Composite Study of the Coeliac Axis Artery.* Ann. Surg., vol. 65, pp. 159-169, 1917.
12. Romodanowskaja, Z. *Die Arterien der Bauchspeicheldrüse.* Zeitschr. f. Anat. u. Entwicklungsgesch., Bd. 79, S. 506-514, 1926.
13. Adachi, B. *Das Arteriensystem der Japaner.* Bd. 2, Marusen Co., Kyoto, 1928.
14. Petrénil, T. *Die Arterien und Venen des Duodenums und des Pankreaskopfes beim Menschen.* Zeitschr. f. Anat. u. Entwicklungsgesch., Bd. 90, S. 234-277, 1929.
15. Wharton, G. K. *The Blood Supply of the Pancreas, with special reference to that of the Islands of Langerhans.* Anat. Rec., vol. 53, pp. 55-81, 1932.

16. Ziegler, H. R. Excision of the Head of the Pancreas for Carcinoma with studies of its blood supply. Surg., Gynec., & Obst., vol. 74, pp. 137-145, 1912.
17. Wilkie, D. P. D. The Blood Supply of the Duodenum with Special Reference to the Supraduodenal Artery. Surg., Gynec., & Obst., vol. 13, pp. 399-405, 1911.
18. Edwards, L. F. The Retroduodenal Artery. Anat. Rec., vol. 81, pp. 351-355, 1911.

REFERENCES REVIEWED BUT NOT CITED

1. Allen, W. F. The Blood-vascular system of the Loricati. Proc. Wash. Acad. Sc., vol. 7, pp. 29-137, 1906.
2. Bergmann, L. "Über einige seltene Anomalien der Arteria coelica. Zeitschr. f. Anat. u. Entwicklungsgesch., Bd. 101, S. 525-533, 1933.
3. Bichat, De Xavier. Traité D'Anatomie Descriptive. Tome 4, J. A. Brosson et Gebon, Paris, 1819.
4. Bardeleben, K. v. Handbuch der Anatomie des Menschen. Bd. 6, Gustav Fischer, Jena, 1902.
5. Brown, I. "Über die Entwicklung und Wanderung" der Zweige der Aorta abdominalis beim Menschen. Anat. Hefte, Bd. 36, S. 407-550, 1908.
6. Brunshwig, A. The Surgery of Pancreatic Tumors. C. V. Mosby Co., St. Louis, 1942.
7. Cloquet, H. Human Anatomy. 4th Ed., Translated by R. Knox, Wells & Lilly, Boston, 1830.
8. Cunningham, D. J. Textbook of Anatomy. 7th Ed. (J. C. Brash & E. B. Jamieson), Oxford University Press, New York, 1937.
9. Duval, P., J. C. Roux, & H. Béclère. The Duodenum--Medical, Radiologic, & Surgical Studies. Translated by E. P. Quain, C. V. Mosby Co., St. Louis, 1923.
10. Eaton, P. B. The Coeliac Axis. Anat. Rec., vol. 13, pp. 369-374, 1917.
11. Grant, J. C. B. A Method of Anatomy. Wm. Wood & Co., Baltimore, 1937.
12. Grey, H. Anatomy of the Human Body. 24th Ed. (W. H. Lewis), Lea & Febiger, Philadelphia, 1942.
13. Haasler. Ueber Choledochotomie. Arch. f. Klin. Chir., Bd. 53, S. 289-305, 1899.
14. Haller, A. H. Boerhaave prae lectiones acad. Volum 1, Taurini, 1742. (from Petréni)
15. Haynes, I. S. A Manual of Anatomy. W. B. Saunders, 1896.

16. Jonnesco, Th. *Traite D'Anatomie Humaine*. (P. Poirier & A. Charpy), Tome 1, Fasc. 1, Masson et Cie, Paris, 1912.
17. Kehr, H. *Chirurgie der Gallenwege*. N. Dtsch. Chir., Bd. 3, S. 36-39, 1913.
18. Kopsch, Fr. *Raubers Lehrbuch der Anatomie des Menschen*. 8 Aufl., Bd. 6, Georg Thieme, Leipzig, 1909.
19. Kostinovitch, L. I. A Case of Simultaneous Occurrence of a Number of Variations of the Visceral Branches of the Abdominal Aorta. *Anat. Rec.*, vol. 67, pp. 399-403, 1937.
20. Lagneuse, E. *Traite D'Anatomie Humaine*. (P. Poirier et A. Charpy), 3rd Ed., Tome 4, Fasc. 3, Masson et Cie, Paris, 1914.
21. Lyssenkow, N. K. Fall einer seltenen Variation des Ursprungs der A. hepatica. *Anat. Anz.*, Bd. 75, S. 184-187, 1932.
22. Maeda, W. Zur topographischen Anatomie des Duodenum der Japaner. *Acta Scholae Medicinalis Universitatis Imperialis in Kioto*, Bd. 7, S. 74, 1924. (from Petren & Adachi)
23. Nichols, N. A. The Variational Anatomy of the Hepatic & Cystic Arteries. *Anat. Rec.*, vol. 85, p. 329, 1943.
24. Mitchell, G. A. A Rare Abnormality of the Hepatic Artery. *Brit. J. Surg.*, vol. 22, pp. 178-180, 1934.
25. Morris, H. *Human Anatomy*. 10th Ed. (J. P. Schaeffer), Blakiston, Philadelphia, 1942.
26. Munger, R. S. Report of an Unusual Coeliac-Mesenteric Trunk with Unique Distribution and Anastomoses. *Anat. Rec.*, vol. 80, pp. 55-59, 1941.
27. Nowak, E. Zur Technik der Duodenalresektion bei Ulcus duodeni. *Arch. f. Klin. Chir.*, Bd. 116, S. 518-541, 1921.
28. Opie, E. L. *Diseases of the Pancreas*. J. B. Lippincott Co., Philadelphia, 1910.
29. Piersol, G. A. *Human Anatomy*. 9th Ed. (C. G. Huber), J. B. Lippincott Co., Philadelphia, 1930.
30. Quain, J. *Elements of Anatomy*. 11th Ed., vol. 2, Part 2, Longman's, Green, & Co., New York, 1914.
31. Reeves, T. B. A Study of the Arteries Supplying the Stomach and Duodenum and their Relation to Ulcer. *Surg., Gynec., & Obst.*, vol. 30, pp. 374-385, 1920.

32. Robson, A. W. M. & B. C. A. Moynihan. Diseases of the Pancreas & their Surgical Treatment. W. B. Saunders & Co., Philadelphia, 1902.
33. Sobotta, J. & J. P. McMurrich. Atlas of Human Anatomy. 4th Ed., vol. 3, G. E. Stechert & Co., New York, 1936.
34. Spalteholz, W. Hand-atlas of Human Anatomy. 7th Ed. in English, vol. 2, J. B. Lippincott Co., Philadelphia.
35. Spiegelius, A. *Adr. Spigelii opera omnia* livre VI. Amsterdami, 1645. (from Petron)
36. Sweet, J. E. The Surgery of the Pancreas. International Clinics, 25th Series, vol. 4, pp. 293-357, 1915.
37. Tallridge, G. K. Un cas d'anomalie rare de l'artere hepatique. *Anat. Anz.*, Bd. 35, S. 433-435, 1933.
38. Tandler, J. Über die Varietäten der Arteria Coeliaca und deren Entwicklung. *Anat. Hefte*, Bd. 25, S. 475-502, 1904.
39. Toldt, C. An Atlas of Human Anatomy. 2nd Ed., vol. 2, Macmillan Co., New York, 1923.
40. Usadel, W. Untersuchungen über die Gefäßversorgung des Magens zum Zweck seiner plastischen Verwendbarkeit. *Arch. f. Klin. Chir.*, Bd. 133, S. 401-427, 1925.
41. Wiart, P. Recherches sur l'anat. topogr. et les voies d'accès du choledoque. Thèse Paris, 1899. (from Petron)
42. Yule, E. The Arterial Supply to the Duodenum. *J. of Anat.*, vol. 61, pp. 344-345, 1927.

Fig. 1. Diagrammatic representation of the typical arterial supply of the pancreas. Anterior aspect.

Fig. 2. The most common arrangement of the anterior pancreatic arcade. Anterior aspect with pylorus and first part of duodenum reflected to the right. (Modified from Petré)

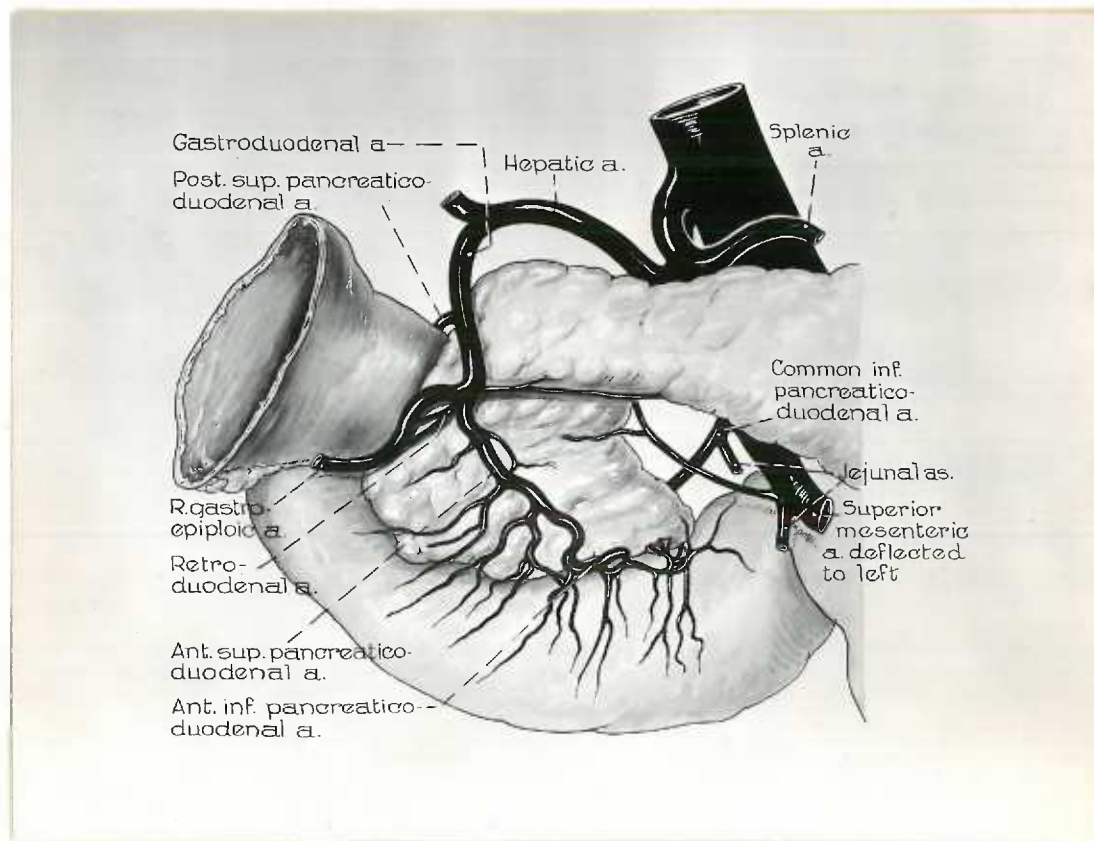
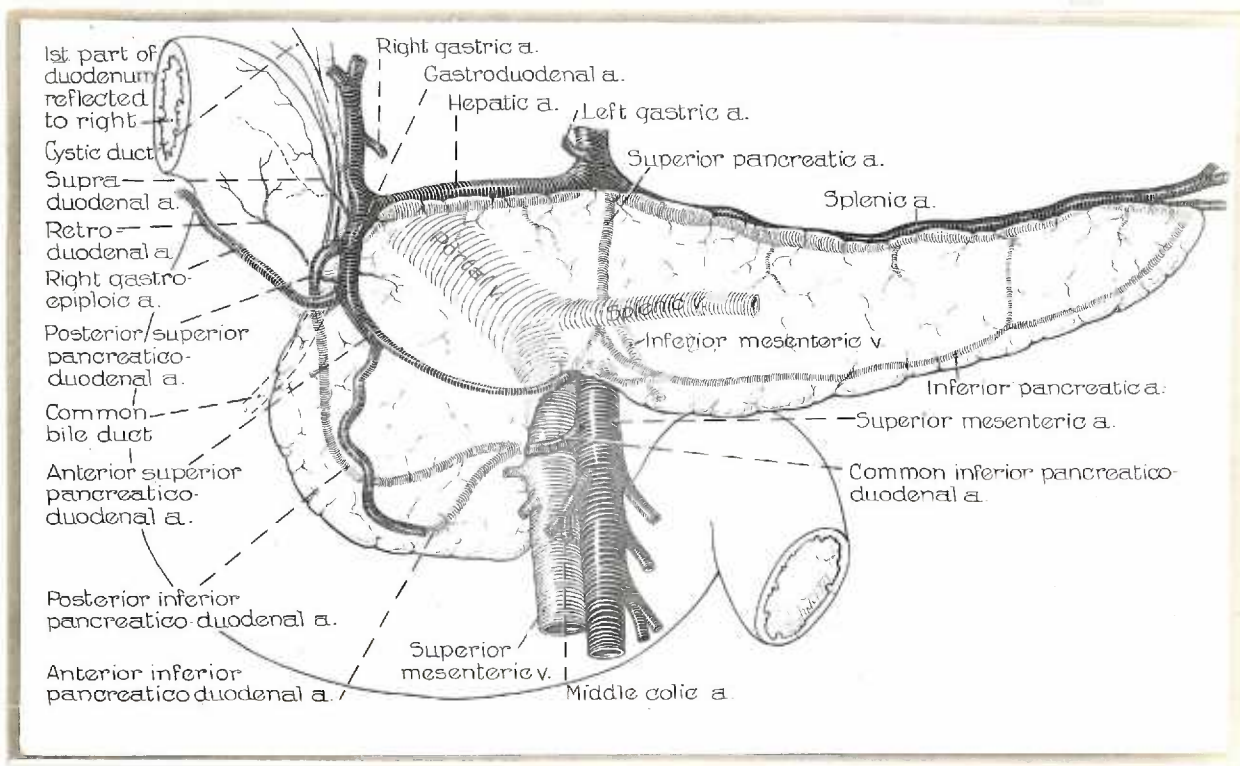


Fig. 3. Posterior aspect of the specimen in Fig. 2 showing relations present in 14 per cent of cases. The gastroduodenal artery lies directly anterior to the common bile duct. (Modified from Petron)

Fig. 4. The most common arrangement of the posterior pancreatic arcade. Posterior aspect with pylorus and first part of duodenum reflected to the right. (Modified from Petron)

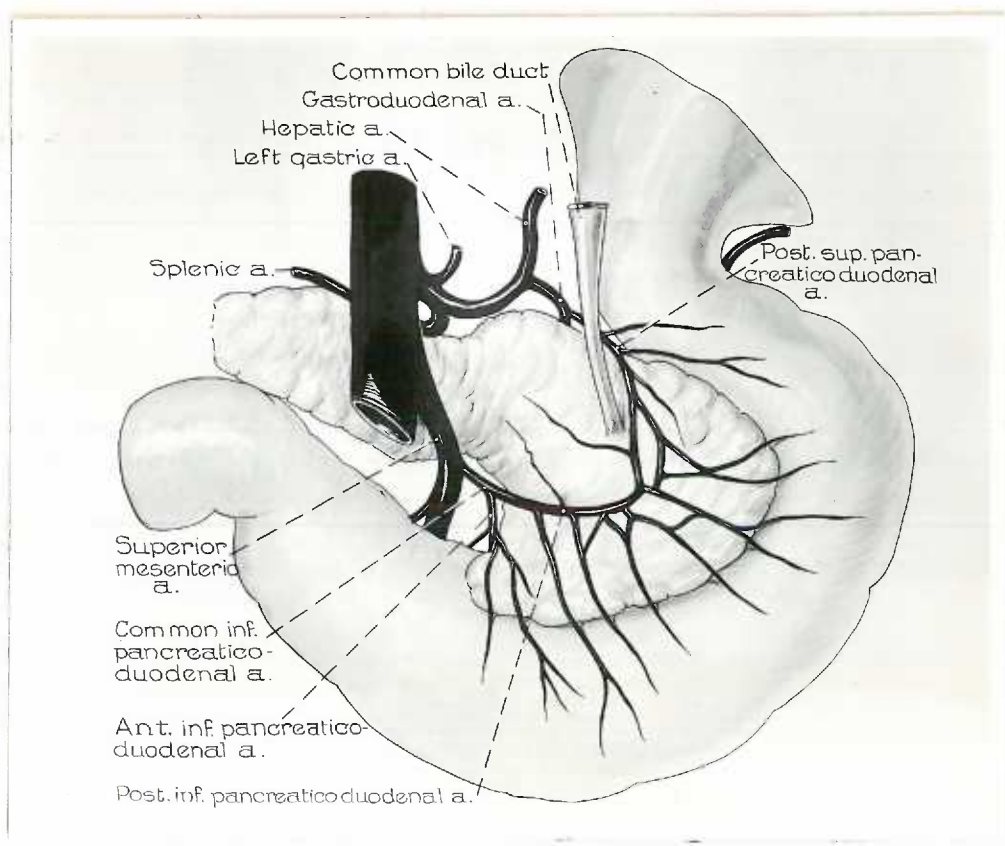
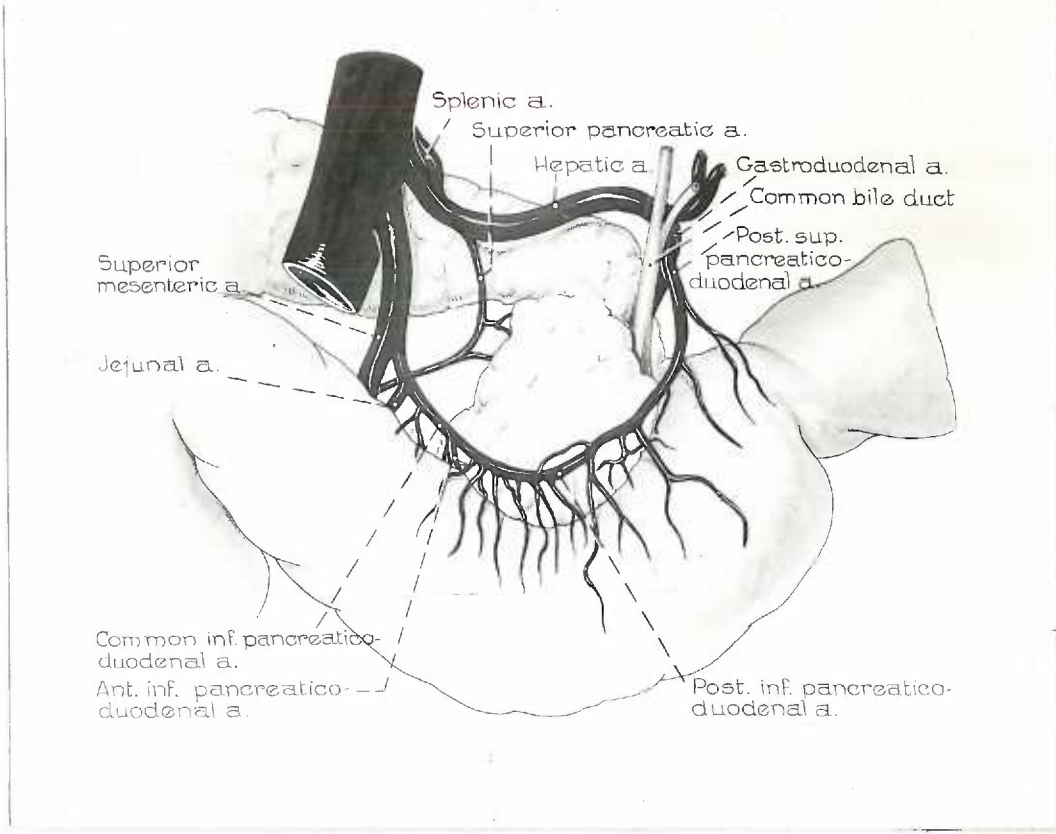


Fig. 5. Vascular distribution about the common bile duct as viewed from the right when the duodenum and attached pancreas are reflected medially.

(Modified from Rio Branco)

Portal v.

Hepatic a.

Gastroduodenal a.

Common bile-
duct

Supraduodenal a.

Posterior superior
pancreatico-
duodenal a.

Posterior superior
pancreatico-
duodenal v.

Head of pancreas
incised to expose
common bile duct

First, second,
and third | Parts
of
duodenum

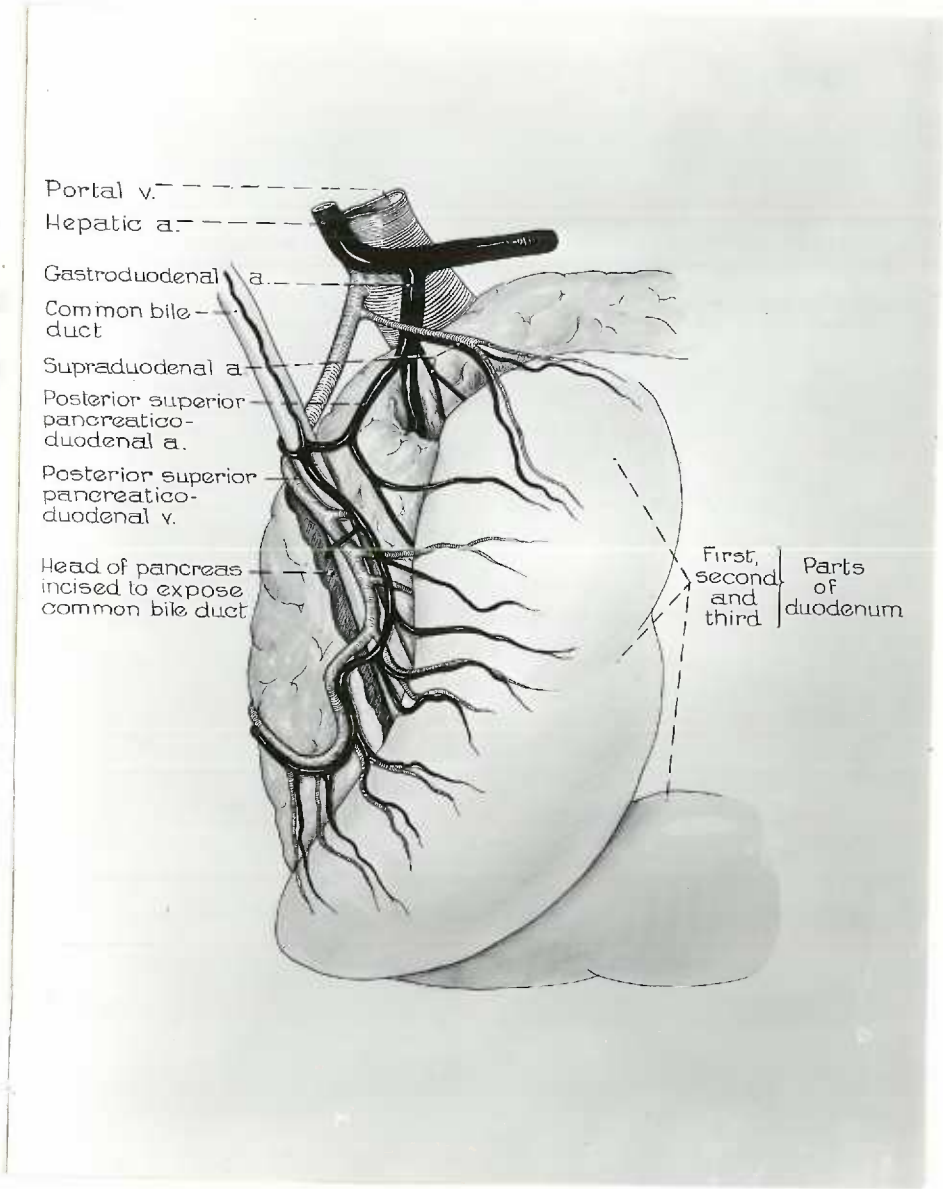


Fig. 6. Specimen in which the middle colic artery takes origin from the superior pancreatic. The transverse colon and stomach are reflected upward. Note that the right colic artery passes directly to the hepatic flexure of the colon and the middle colic passes to the splenic flexure.

